

Research article

Open Access

Atypical glandular cells in conventional cervical smears: Incidence and follow-up

René Scheiden*^{1,2,3}, Catherine Wagener¹, Ulrich Knolle¹, Walter Dippel² and Catherine Capesius³

Address: ¹Division of clinical cytology, National Health Laboratory, L – 1950 Luxembourg, ²Division of pathology, National Health Laboratory, L – 1950 Luxembourg and ³Morphologic Tumour Registry, L – 1950 Luxembourg

Email: René Scheiden* - rmt@lns.etat.lu; Catherine Wagener - rmt@lns.etat.lu; Ulrich Knolle - rmt@lns.etat.lu; Walter Dippel - rmt@lns.etat.lu; Catherine Capesius - rmt@lns.etat.lu

* Corresponding author

Published: 19 July 2004

Received: 18 March 2004

BMC Cancer 2004, 4:37 doi:10.1186/1471-2407-4-37

Accepted: 19 July 2004

This article is available from: <http://www.biomedcentral.com/1471-2407/4/37>

© 2004 Scheiden et al; licensee BioMed Central Ltd. This is an Open Access article: verbatim copying and redistribution of this article are permitted in all media for any purpose, provided this notice is preserved along with the article's original URL.

Abstract

Background: Atypical glandular cells on cervical smears are often associated with clinically significant uterine lesions. The frequency and accuracy of AGC-NOS (i.e. atypical glandular cells, not otherwise specified) diagnoses, regardless of the gland cell type or the degree of suspicion, and their outcome were investigated.

Methods: From January 1, 1990 to December 31, 1999 a total of 261 patients had an AGC-NOS diagnosis made by conventional cervical Papanicolaou smear interpretation representing 0.05% of all Pap-smears analyzed at the national level. 191 (73.2%) patients had a subsequent histological examination, 8 samples were not representative by origin and were excluded.

Results: Out of 183 AGC-NOS diagnosed, 56.3% (103/183) were associated with tissue-proven precancerous and/or cancerous lesions, 44% being of endocervical and 56% of endometrial origin. 75% of all AGC-patients were asymptomatic. 66.7% (6/9) of the patients with subsequent invasive endocervical adenocarcinoma (AC) and 56% (28/50) of those patients with invasive endometrial AC were without clinical symptoms. 3 patients out of 9 with an invasive endocervical AC were 35 years of age or less. 10.1% and 12.3% of all 'new' tissue-proven invasive endocervical or endometrial AC respectively recorded by the national Morphologic Tumour Registry (MTR) were first identified by a cytological AGC-NOS diagnosis.

Conclusion: Our findings emphasize the importance of the cytological AGC-category even in the absence of a precise origin or cell type specification. 56% of the AGC-diagnoses being associated with significant cancerous or precancerous conditions, a complete and careful evaluation is required.

Background

According to the 'original' definitions of "The Bethesda-

System" (TBS, 1989, 2001) for reporting cervico-vaginal cytological diagnoses and in analogy to the Munich II-

Table 1: Classification of Munich (II), modified by Soost in 1989 [5].

Class	Cytological description	Recommendation
I	Normal cells	/
II	Regenerative cells, immature metaplastic cells, important degenerative or inflammatory changes, para- and hyperkeratinizing cells. Normal endometrial cells even after the menopause.	cytological control if necessary (with or without anti-inflammatory or hormonal treatment)
III	Important degenerative, iatrogenic or inflammatory changes of the cells where benignity or malignancy cannot be diagnosed with certainty even if the smear is adequately prepared.	short-term cytological control if necessary after anti-inflammatory or hormonal treatment, or immediate histological control
IIID	Mild to moderate dysplasia (CIN I and II)	cytological control in 3 months
IIIG	Abnormal cells of the glandular epithelium whose carcinomatous nature cannot be excluded with certainty; if possible with an indication of the endometrial, endocervical or extra-uterine origin of the cells.	cytological or histological control
IV a	Severe dysplasia or carcinoma in situ (CIN III)	histological control
IV b	Severe dysplasia or carcinoma in situ; invasive carcinoma not excluded	histological control
V	Invasive epidermoid carcinoma of the uterine cervix; adenocarcinoma, indicating if possible the endometrial, endocervical or extra-uterine origin of the cells. Other malignant tumours.	histological control

classification modified by Soost in 1989 (Table 1) the current study focuses on the 'former' atypical glandular cells of undetermined significance (AGUS/TBS versus Class III G/MUNICH II) diagnosed during the 1990's in a non-academic laboratory [1-7]. It has been generally accepted that the cervical cyto-histological correlation can be considered as one method, predominantly used by cytology laboratories to conduct quality assurance [6,7]. The AGUS, now AGC-NOS (i.e. atypical glandular cells, not otherwise specified) category and its counterpart ASCUS (atypical squamous cells of undetermined significance) were often excluded from cyto-histological correlations [8,9]. As a follow-up study of AGC-diagnoses, we reviewed our results in order to determine the frequency of the AGC diagnoses in general and the age distribution of the patients. Beside we examined time trends and their correlation with the corresponding available histopathological results.

Methods

From January 1, 1990 to December 31, 1999, a total of 566.809 cervico-vaginal smears were screened at the central division of clinical cytology of the National Health Laboratory (NHL) in Luxembourg (Western Europe). All smears were conventional smears and no liquid based preparation was used. 261 cases were categorized as AGUS versus Cl III G diagnoses and correlated with the histopathological diagnoses collected by the National Morphologic Tumour Registry (MTR).

The AGUS category was defined by the TBS (1989) as atypical glandular cells of undetermined significance showing either endocervical or endometrial differentiation, with nuclear atypia that exceeds obvious reactive or reparative changes including endocervical in situ adenocarcinomas but lacking unequivocal features of invasive adenocarcinomas [1]. By analogy, the Munich II-classification modified by Soost (Table 1), used in our laboratory, defines the Cl III G as abnormal cells of the glandular epithelium, whose carcinomatous nature cannot be excluded with certainty, and recommends, if possible, a statement concerning the endometrial, endocervical or extra-uterine origin of the cells [5]. During the observation period 1990 to 1999 the AGUS/Cl III G – diagnoses in our series were *not* qualified, neither by site, nor by criteria favoring reactive or neoplastic aspects. Patients with benign endocervical or endometrial cell changes and patients with unequivocally malignant glandular cells described by the TBS were not considered. In this study, we have used the term 'AGC-NOS' for 'atypical glandular cells, not otherwise specified' of the new Bethesda 2001 nomenclature instead of AGUS.

To guarantee the technical quality of the smears, all the material needed to take samples, transport and prepare the smears (wooden "Ayre" spatula, cotton swab, flask for transport, ether-alcohol fixative, slides) were provided to the general practitioners and gynecologists collaborating as 'smear takers' [10]. The smears were then analyzed by cytotechnologists with a maximal work load of 76 Harris-

Shorr stained slides per day, and 8 slides chosen at random for double-check [11]. All AGC-NOS cases were examined by the chief cytotechnologist as well as the cytopathologist responsible for the original cytological diagnosis. To ensure diagnostic quality, the cytopathologist had access to all case histories with a high rate of histologic correlates and which are centralized at the national histopathology division of the NHL.

The cyto-histological correlation being a common component of quality assurance and improvement programs in cytopathology laboratories, we analysed our AGC-NOS cases to provide a reference database for intra- and inter-laboratory comparison of performance [6,12,13]. The quality assurance monitors were the cyto-histological correlations and the AGC-NOS/in situ AC versus the AGC-NOS/invasive AC ratio, including the comparison with the AC diagnosed in a well-defined area (i.e. patients of all nationalities living in the Grand-Duchy of Luxembourg). All the cancer cases were registered during the study period (1990–1999) by the national cancer registry, which records *all* in situ and invasive cancers of all sites diagnosed by morphological methods (i.e. histology and cytology) in Luxembourg [8,14,15]. With the access to all reports of the central department of pathology, the files of the national MTR and the 'governmental' administrative population data of all inhabitants, only 24 of the 261 patients were lost for follow-up. 16 patients quit the country and 8 patients died within 3 months after the cytological diagnosis. The causes of death were not related to uterine disease.

Patients were stratified into three different classes: those having histopathological examinations with precise diagnoses, those with repeat cytological screening only, and those without follow-up data. The follow-up observation period after the last AGC-NOS diagnosis in December 31, 1999 was at least 24 months. The cyto-histological correlations were recorded for patients with a subsequent histological tissue examination (i.e. cervical micro-biopsy, conization, endocervical and/or endometrial curettage and hysterectomy specimens). The results of the most representative of these procedures and with the most serious histological diagnosis were retained. For the purpose of the present study we reviewed the cytological (CW) and the histological (RS) slides of all AGC-cases.

The number of in situ or invasive, endocervical and endometrial adenocarcinomas initially detected by cervico-vaginal smears with an AGC-NOS diagnosis were compared with *all* 'new' tissue-proven in situ or invasive, endocervical or endometrial adenocarcinomas diagnosed in the Grand-Duchy of Luxembourg during the review period and registered by the MTR [14,15]. Out of 495 patients with an invasive uterine AC only 30 patients had

a preceding Pap-smear with an unequivocal malignant cytological diagnosis. Duplicate registrations were excluded. The tumour stages were classified by the TNM system of the 'Union Internationale Contre le Cancer'/UICC, 1997 [16].

The chi-square-test (χ^2) with the Yates correction was used to determine the statistical significance of the differences in the time trends of the AGC-diagnoses over the study period from 1990 to 1999. The level of significance was <0.05.

Results

566.809 conventional cervico-vaginal Pap-smears were examined during the 10-years observation period (Table 2) [17]. An AGC diagnosis 'not otherwise specified' was made in 261 cases corresponding to 0.05% of all cervical Pap-smears. 24 patients (9.2%) were lost to follow-up and 46 patients (17.6%) had repeat cytology only. 70 AGC patients (26.8%) had no histological follow-up data. From 191 patients (73.2%) who had a subsequent histological examination only 8 samples were not representative by site (i.e. exocervical biopsies) and had to be excluded. 71 patients had hysterectomy preceded by a curettage of the cervix and the corpus.

In Fig. 1, the age distribution is represented. 5.4% of the 261 patients with an AGC-NOS diagnosis were 35 years of age or less, whereas 94.6% were aged 36 years and above. The mean age of the patients was 54.9 years (range 18 to 93 years).

63 (24.1%) of the 261 women with an AGC-NOS diagnosis had clinical symptoms (i.e. abnormal vaginal bleeding), whereas 198 (75.9%) patients were asymptomatic (Table 3). The 'symptomatic/asymptomatic-ratio' categorised by age groups was 1:13 for women 35 years old or less ($n = 14$) and 1:2.9 (62/185) for women aged 36 years and above. In our series only 1 of the 4 patients with a tissue-proven endocervical adenocarcinoma in situ (AIS) and 3 of the 9 patients with an invasive endocervical AC were symptomatic. 28 of the 50 patients (56%) with a tissue-proven invasive endometrial adenocarcinoma had no clinical symptoms.

Table 4 shows the cyto-histological correlations of 183 AGC-NOS cases. Out of 60 patients (32.8%) with a tissue-proven *endocervical lesion* 28 patients had an intraepithelial squamous cell lesion with endocervical glandular involvement and 3 patients an invasive endocervical squamous cell carcinoma. 120 patients (65.6%) had an *endometrial lesion*. 3 patients had a metastatic adenocarcinoma to the vagina (1.6%), 1 being of rectal origin, 1 of ovarian and 1 of endometrial origin. 56.3% of all histologically verified AGC-NOS diagnoses were associated

Table 2: Demographic data, follow-up and diagnostic procedures (period 1990–1999)

	1990–1994	1995–1999	P-Value	TOTAL
Population *♀ >15 years: at risk	833,964	884,947		
Number of smears (cases)	241,098	325,711	p < 0,05	566,809
AGC-NOS/CI.IIIG**-cases rate per 5 years period	46 0.02%	215 0.07%	p < 0,001	261 (100%) 0.05%
Follow-up (F.u.):*** patients with no histology (no F.u. or cytology only)	8	62	p < 0,05	70 (26.8%)
Available histologic findings ****:	38 (82.6%)	153 (71.2%)	p < 0,05	191 (73.2%)
Diagnostic procedures:				191 (100%)
° cervical biopsies	4	16	p < 0,05	20 (10.4%)
° conization	4	17	p < 0,05	21 (11.0%)
° curettage	14	65	p < 0,05	79 (41.4%)
° hysterectomy	16	55	p < 0,05	71 (37.2%)

*Statec [17]; ** Division of clinical Cytology (NHL); *** 24 months; **** Division of anatomic pathology (NHL)

with a precancerous and/or cancerous lesion. Excluding the 3 metastatic AC, we found 44% (44/100) of the precancerous or cancerous lesions with an *endocervical* origin and 56% (56/100) with an *endometrial* origin.

From nine invasive *endocervical* adenocarcinomas one case (pT1a1) was removed by conization and six cases (pT1b) were treated by hysterectomy. 2 cases diagnosed by biopsy were lost for follow-up. The mean age of these patients was 47 years (range:34–61) 2 patients were 34 and one 35. One of the 34-year-old patients had abnormal vaginal bleeding.

Out of the 50 patients with a biopsy-proven *endometrial* adenocarcinoma, 47 patients had an histological confirmation by curettage and were treated by hysterectomy. 38 (80.9%) of these had an 'early stage' adenocarcinoma of the endometrium limited to the corpus (pT1a:n = 7; pT1b:n = 16; pT1c:n = 15). 7 patients suffered from an AC invading the cervix without extending beyond the uterus (pT2a:n = 4; pT2b:n = 3). 2 women had advanced tumours with an involvement of the serosa (pT3a:n = 2). The mean age of these patients was 64.7 (range: 47–84). 22 patients (22/50; 44%) reported abnormal vaginal bleeding, but 28 women (28/50; 56%) especially those with early stage endometrial AC had no symptoms suggestive of a significant uterine lesion.

We compared our 59 cases of invasive uterine adenocarcinomas identified by a cytological AGC-NOS diagnosis to *all* tissue-proven uterine adenocarcinomas recorded by the national cancer registry during the observation period. 10.1% (9/89; 95% c.i., 0.04–0.16) of the invasive endocervical adenocarcinomas and 12.3% (50/406; 95% c.i., 0.09–0.16) of the invasive endometrial adenocarcino-

mas were first suggested by an AGC-diagnosis and subsequently confirmed by a histological examination.

In Table 5, our findings are compared to those of some other studies published in the 1990's [8,18-23].

Discussion

Although the study period ended before 'Bethesda 2001' it has to be emphasized that the term AGUS has been eliminated to avoid confusion with ASC-US and changed in AGC-NOS for atypical glandular cells not otherwise specified [7].

According to the 'original' Bethesda system (1989) or the Munich II-classification modified by Soost (1989), we defined atypical glandular cells of undetermined significance as cells that were not specified by site, and displaying nuclear atypia that exceeded obvious reactive or reparative changes but lacked unequivocal features of invasive adenocarcinoma [1,3]. This means that an adenocarcinoma cannot be excluded with certainty. We omit a more detailed qualification, as the low reproducibility of this cytological category was generally accepted, especially in view of a precise origin [8,20,23-25]. Unfortunately, despite this restrictive interpretation attitude, we had to accept that 8 patients only had an exocervical 'not representative' histological examination (Table 4). Today our classification system would correspond to the AGC-NOS (i.e. atypical glandular cells not otherwise specified) as recommended by TBS 2001.

AGC-NOS is known as an uncommon cytological diagnosis and should represent for less than 1% of a laboratory's workload [7,26]. In the current study (Table 2) we found 261 'new' AGC-NOS cases diagnosed by cervico-vaginal

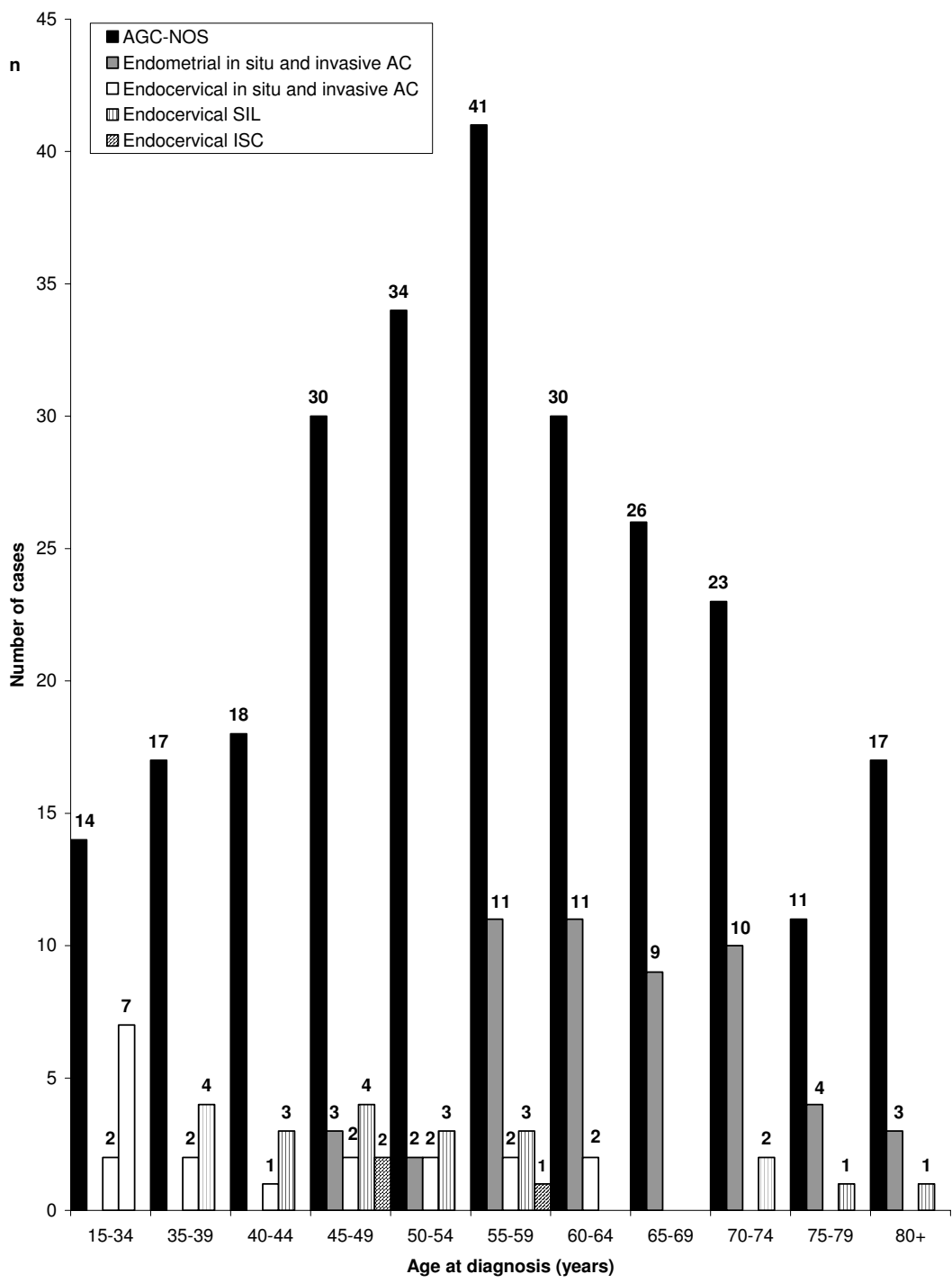


Figure 1
 Age distribution of AGC-NOS diagnoses (n = 261 cases) versus tissue-proven in situ and invasive endocervical (n = 13 cases) and endometrial (n = 53 cases) adenocarcinomas (AC); endocervical squamous intraepithelial lesions (SIL; n = 28 cases) and invasive squamous carcinomas (ISC; n = 3 cases)

Table 3: AGC-NOS patients with and without symptoms (i.e. abnormal vaginal bleeding) stratified by age groups. (n = 261 cases).

Age at diagnosis	no symptoms (%)	abnormal vaginal bleeding (%)
≤34 years	13 (5.0)	1 (0.4)
35–44 years	32 (12.3)	3 (1.1)
45–54 years	51 (19.6)	14 (5.4)
55–59 years	33 (12.6)	9 (3.4)
60–69 years	36 (13.8)	18 (6.9)
70–79 years	21 (8.0)	13 (5.0)
>80 years	12 (4.6)	5 (1.9)
TOTAL: n = 261 (100%)	198 (75.9%)	63 (24.1%)

Table 4: AGC-NOS and cyto-histological correlations (1990–1999)

	90–94	95–99	TOTAL
HISTOLOGICAL DIAGNOSES*	38	153	191
not representative samples	1	7	8
ENDOCERVICAL LESIONS:			
intrauterine device		1	1
microglandular adenoses		2	2
endocervical polyps	2	11	13
SIL**:			
mild dysplasia		3	3
moderate dysplasia	2	4	6
severe dysplasia	1	6	7
squamous in situ carc.***	3	9	12
squamous invasive carc.	1	2	3
adenocarcinoma in situ	2	2	4
adenocarcinoma invasive	2	7	9
ENDOMETRIAL LESIONS:			
WNL****	3	19	22
Arias-Stella changes	1	2	3
glandulo-cystic hyperplasia		5	5
submucosal leiomyoma	3	5	8
endometrial polyps	6	20	26
atypical endometrial hyperplasia	1	2	3
adenocarcinoma in situ	1	2	3
adenocarcinoma invasive	9	41	50
metastatic adenocarcinomas of rectal, ovarian, endometrial origin to the vagina		3	3

* histology: biopsy, cone, curettage, hysterectomy ** SIL: squamous intraepithelial lesion with endocervical glandular involvement *** carc.: carcinoma **** WNL: within normal limits

cytology in our population, representing an AGC rate of 0.05% and increasing from 0.01% in 1990 to 0.09% in 1999. Other laboratories reported AGC rates ranging from 0.09% to 2.5% [8,18,20-22,27-29]. The reason why the prevalence of AGC in our series is considerably lower than that reported in other studies may be due to the exclusion of 25 cases with atypical 'epithelial' cells at the beginning of the 1990's. At revision, these cases had a glandular histopathological correlate (i.e. nine endocervical polyps, fourteen endometrial polyps, one glandular-cystic hyperplasia and one endometrial AC). During the observation

period (1990–1999), there was a significant continuous increase ($p < 0.001$) in cytological AGC-NOS diagnoses. This was probably due to a more intensive education and training of the cytologists in our institution and a more defensive cytological practice in relation with a lack of reliable cytological criteria [26]. In our series the AGC-NOS category was not systematically used instead of unequivocal malignant glandular cells diagnoses ($n = 30$ cases) which were reported separately. Unfortunately we found an increasing reluctance of the cytologists to give an unequivocal prediction of glandular neoplasia. As the

Table 5: Histological follow-up findings of patients with atypical glandular cells of undetermined significance-not otherwise specified (AGUS-NOS) compared to the results of other studies with AGUS including subqualifications (reactive/neoplastic/NOS) [18].

STUDY	NUMBER OF AGUS-cases	BENIGN (%)	FOLLOWING-UP FINDINGS ADENOCARCINOMA (%)	SIL*** (%)
BASE et al ¹⁹ (1994)	44	9 (20)	0 (0)	35 (80)
BURJA et al ²⁰ (1999)	64	26 (41)	3 (5)	35 (54)
DUSKA et al ²¹ (1998)	73	48 (66)	19 (26)	6 (8)
KENNEDY et al ²² (1996)	77	60 (78)	10 (13)	7 (9)
JONES and NOVIS ⁸ (1996)	293*	141 (48)	13 (4.5)	116 (40)
RAAB et al ²³ (1997)	116	50 (43)	16 (14)	50 (43)
SOOFER and SIDAWY ¹⁸ (2000)	69	52 (75)	7 (10)	10 (15)
OUR SERIES	183**	80 (44)	66 (36)	28 (15)

* The remaining 7.5% of patients had combinations or other significant lesions. ** The remaining 5.0% of patients had other significant lesions i.e. 3 endometrial adenomatous hyperplasias; 3 metastatic vaginal (2) and ovarian (1) adenocarcinomas; 3 invasive endocervical squamous carcinomas. *** SIL: squamous intraepithelial lesions.

number of unequivocal malignant glandular cell diagnoses decreased from 21 cases in the period 1990–1994 to 9 cases in the period 1995–1999, a concomitant decrease in the issue of reports giving a precise prediction of glandular neoplasia must be admitted too. This may inflate the follow-up rate of cancer associated with AGC-NOS as well. At the rescreening for the purposes of the present study 13 cases (5%) of the 261 smears with an AGC-diagnosis had to be reclassified as malignant cytological diagnoses. On the other hand the increase in invasive adenocarcinomas of both cervix and particularly endometrium associated with AGC-NOS cytological prediction may also be attributed to changes in clinical and in cytological practices. In 1992, an organized national breast cancer screening program started targeting women between 50 and 64 years and reaching a participation rate of more than 50%. It seems that the close multidisciplinary collaboration (gynecologists, radiologists, cytopathologists) initiated by this program has had a secondary sensitizing effect on the concerned health care professionals and the invited women as well. So it seems that older women were targeted for PAP-smears more frequently after 1992. Perhaps this has affected partially the predominance of endometrial lesions following AGC. The fact that all our clinicians used a cotton swab to obtain the endocervical sample may be disturbing. It has been demonstrated by some authors that this is an inferior technique for obtaining a sample from the cervical canal and emphasis is placed on the cytobrush in many countries. The high percentage of early stage endometrial adenocarcinomas without symptoms and our finding that primary diagnosis of malignancy was made by cytology in a significant number of cases in our population do not support the opinion that the use of cotton swab is an obsolete technique. The file review in our laboratory suggests, that

there is no significantly increased likelihood that cytology was taken in women clinically suspected having endometrial neoplasia. Indeed, 33% of the patients with an endocervical AC and 56% with an endometrial AC were asymptomatic (Table 3). These observations are in contrast to the findings of Hare et al. [29] who describe 28.3% asymptomatic patients with invasive endocervical AC diagnosed with the cytobrush technique. All of these 15 endometrial AC were symptomatic. Jackson et al. [30] reported a series of 34 asymptomatic cases giving a final outcome of cervical glandular neoplasia in 45% including just one case of invasive disease.

It is generally accepted that the cytological distinction between reactive, inflammatory, irritative and dysplastic or neoplastic altered squamous and/or glandular proliferations is complex and may be controversial for the cytopathologists and the surgical pathologists alike [31,32]. In a study of Raab SS and co-workers [23] an interobserver variability of Papanicolaou smear diagnoses of atypical glandular cells of undetermined significance with a sensitivity of only 63% and a specificity of 58% is reported. Our tissue-proven follow-up findings are summarized in Table 4, and regroup the spectrum of potential pitfalls, that had also been reported by other groups [30,33–38]. So 31 of our AGC-cases were associated with tissue-proven endocervical squamous lesions, 28 corresponding to squamous intraepithelial lesions and 3 to invasive squamous carcinomas and benign lesions such as irritated endocervical and endometrial polyps or glandular hyperplasia. 3 cases were Arias-Stella reaction changes. Due to the lack of sufficiently precise cytological criteria of atypical glandular cells, considerable inter-observer variability is associated with the recognition of AGC. This may also explain the persistent percentage of dysplastic lesions

of squamous cell origin in our series as well as in other studies (Table 5). The 'former' AGUS is associated with a clinically significant lesion of various proportions, ranging from 17% to up to 80% of patients [8,18,20-22,27,28]. We found clinically significant lesions in 56% of our AGC-NOS cases (Table 4) suggesting that all patients with an AGC-NOS diagnosis require further investigation.

The age distribution of the patients represented in Fig. 1 confirmed that the AGC-NOS diagnoses concerned more frequently women of age 36 and above, indicating that this cytologic diagnosis should be made carefully in patients under 30 years of age to avoid over-diagnosis and over-treatment.

Referring to the IAC Task Force Summary of 1998, there was no clear consensus regarding patient management until 2001 [26]. In analogy to the guidelines for managing women with AGC issued in 2001 by the American Society for Colposcopy and Cervical Pathology (ASCCP), we recommend today a complete and careful evaluation [39-41]. According to Soofer et al. [18] and Hare et al. [29] and in order to avoid an inappropriate patient management due to a misleading qualification (endocervical versus endometrial origin; squamous or glandular cell type; cell atypias favouring a reactive or neoplastic etiology) we support a step-by-step approach of each AGC-NOS diagnosis, including colposcopic examination, followed by a curettage of the cervix *and* of the corpus to obtain an unequivocal histological diagnosis.

Exfoliative cytology has been proven to be an efficacious technique for the detection of precancerous and cancerous squamous lesions of the cervix. This is not true for endocervical and especially endometrial lesions of glandular origin [7,41]. As a more detailed sub-classification of the AGC category may be an additional factor in cytologic-histological discrepancies we prefer not to qualify AGC diagnoses. Although the AGC-rate reported here is one of the lowest described, our series presents the highest, mostly early stage, malignant rates with predominantly endometrial lesions, despite the use of cotton swabs. In contrast with some other studies, however, most of the lesions were in fact glandular, not squamous. [18-23]

Conclusion

As 56% of the patients in our series had significant cancerous and precancerous conditions found, patients with not qualified AGC-diagnosis require complete and careful evaluation.

Competing interests

None declared.

Author's contributions

All authors (RS, CW, UK, WD, CC) collaborated intensely on all aspects of the manuscript, from research design to data preparation to presentation. RS and CW reviewed the slides. RS and WD wrote and all authors approved the final manuscript.

Acknowledgments

We thank Mrs Mireille Braun and Mrs Martine Becker for their helpful assistance during the preparation of the manuscript.

The study received financial support from the national Morphologic Tumour Registry (RMT a.s.b.l.). The opinions stated in this document are those of the authors and do not necessarily represent the official position of the RMT.

References

1. Kurman RJ, Solomon D: **The Bethesda System for reporting cervical/vaginal cytological diagnosis.** Berlin, Heidelberg, New York: Springer-Verlag; 1994.
2. **National Cancer Institute Workshop. Bethesda System for reporting cervical/vaginal cytologic diagnosis.** *J Am Med Ass* 1989, **262**:931-934.
3. Schenck U, Soost HJ, ed: **Befundwiedergabe in der Zytologie: Münchner Nomenklatur II und Bethesda System 1991.** In *Referatband der 13. Fortbildungstagung für klinische Zytologie.* München: Märkl-Druck 1995:224-233.
4. Smith JHF: **Review: Bethesda 2001.** *Cytopathology* 2002, **13**:4-10.
5. Schenck U, Soost HJ, ed: **Nomenklatur und Befundwiedergabe in der gynäkologischen Zytologie.** In: *Referatband der 10. Fortbildungstagung für klinische Zytologie.* München: Märkl-Druck 1989:306-314.
6. Koss LG: **The Papanicolaou test for cervical cancer detection. A triumph and a tragedy.** *JAMA* 1989, **261**:737-743.
7. Solomon D, Davey D, Kurman R, Moriarty A, O'Connor D, Prey M, Raab S, Sherman M, Wilbur D, Wright Jr, Young N: **The 2001 Bethesda System. Terminology for reporting results of cervical cytology.** *JAMA* 2002, **287**:2114-2119.
8. Jones AB, Novis DA: **Cervical biopsy-cytology correlation. A College of American Pathologists Q-Probes Study of 22439 Correlations in 348 Laboratories.** *Arch Pathol Lab Med* 1996, **120**:523-531.
9. Tritz DM, Weeks JA, Spires SE, Sattich M, Banks H, Cibull ML, Davey DD: **Etiologies for non-correlating cervical cytologies and biopsies.** *Am J Clin Pathol* 1995, **103**:594-597.
10. Scheiden R, Knolle U, Wagener C, Wehenkel AM, Capesius C: **Cervical Cancer Screening in Luxembourg.** *EJC* 2000, **36**:2240-2243.
11. Pundel JP, Lichtfus C: **Modification de la coloration cytologique des frottis vaginaux à l'hématoxyline-Shorr.** *Gynaecologia* 1957, **144**:58.
12. Kraemer BB: **Quality assurance activities of the College of American Pathologists.** *Acta Cytol* 1989, **33**:434-438.
13. Rohr LR: **Quality assurance in gynaecologic cytology.** *Am J Clin Pathol* 1990, **94**:754-758.
14. Capesius C, Scheiden R, Groff P, Kanz R, Wehenkel CL, Juchem JP: **Monographies des nouveaux cas de cancer au Grand-Duché de Luxembourg-années 1994-1995-1996-1997-1998-1999.** *Registre Morphologique des Tumeurs (ed) Luxembourg* 2001 [<http://www.cancer-registry.lu>].
15. Capesius C, Scheiden R, Groff P, Schneider F, Kanz R, Wehenkel CI: **Monographies des nouveaux cas de cancer au Grand-Duché de Luxembourg - années 1990-1991-1992-1993.** *Registre Morphologique des Tumeurs (ed) Luxembourg* 1994 [<http://www.cancer-registry.lu>].
16. Sobin LH, Wittekind CH: **TNM-Classification of Malignant Tumours. Fifth edition, UICC.** New York: Wiley-Liss, Inc; 1997:141-151.
17. Statec: **Données de la population 1990-1999.** *Service central de la statistique et des études économiques. Luxembourg: Ministère de l'Etat* 2000.

18. Soofer SB, Sidawy MK: **Atypical Glandular Cells of undetermined significance. Clinically significant lesions and means of patient follow-up.** *Cancer Cancer cytopathol* 2000, **90**:207-14.
19. Base S, Kannan V, Kline TS: **Abnormal endocervical cells. Really abnormal? Really endocervical?** *Am J Clin Pathol* 1994, **101**:708-13.
20. Burja IT, Thompson SK, Sawyer WL Jr, Shurbaji MS: **Atypical glandular cells of undetermined significance on cervical smear. A study with cytohistologic correlation.** *Acta Cytol* 1999, **43**:351-356.
21. Duska LR, Flynn CF, Chen A, Whall-Strojwas D, Goodman A: **Clinical evaluation of atypical glandular cells of undetermined significance on cervical cytology.** *Obstet Gynecol* 1998, **91**:278-282.
22. Kennedy AW, Salmieri SS, Wirth SL, Biscotti CV, Tuason LJ, Travarca MJ: **Results of the clinical evaluation of atypical glandular cells of undetermined significance (AGUS) detected on cervical cytology screening.** *Gynecol Oncol* 1996, **63**:14-18.
23. Raab SS, Snider TE, Potts SA, MC Daniel HL, Robinson RA, Nelson DL, Sigman JD, Thomas PA: **Atypical glandular cells of undetermined significance; diagnostic accuracy and interobserver variability using select cytologic criteria.** *Am J Clin Pathol* 1997, **107**:299-307.
24. Simsir A, Hwang S, Cangiarella J, Elgert P, Levine P, Sheffield MV, Roberson J, Talley L, Chhieng DC: **Glandular cell atypia on Papanicolaou smears: interobserver variability in the diagnosis and prediction of cell of origin.** *Cancer* 2003, **99**(6):323-30.
25. Chhieng DC, Cangiarella JF: **Atypical glandular cells.** *Clin Lab Med* 2003, **23**(3):633-57.
26. Solomon D, Frable WJ, Vooijs GP, Wilbur DC, Amma NS, Davey DD, Knight BK, Luff RD, Meisels A, Marin J, Rosenthal DL, Saner T, Stoler M, Suprun HZ, Yamauchi K: **ASCUS and AGUS criteria, IAC Task Force Summary.** *Acta Cytol* 1998, **42**:16-24.
27. Eddy GL, Ural SH, Strumpf KB, Wojtowycz MA, Piraino PS, Mazur MT: **Incidence of atypical glandular cells of uncertain significance in cervical cytology following introduction of the Bethesda System.** *Gynecol Oncol* 1997, **67**:51-5.
28. Raab SS, Geisinger KR, Silverman JF, Thomas PA, Stanley MW: **Interobserver variability of a Papanicolaou smear diagnosis of atypical glandular cells of undetermined significance.** *Am J Clin Pathol* 1998, **110**:653-9.
29. Hare AA, Duncan AR, Sharp AJ: **Cytology suggestive of glandular neoplasia: outcomes and suggested management.** *Cytopathology* 2003, **14**:12-18.
30. Jackson SR, Hollingworth TA, Anderson MC, Johnson J, Hammond RH: **Glandular lesions of the cervix: cytological and histological correlation.** *Cytopathology* 1996, **7**:10-16.
31. Ismail SM, Colcough AB, Dinnen JS, Eakins D, Evans DM, Gradwell E, O'Sullivan JP, Summerell JM, Newcombe RG: **Observer variation in histopathological diagnosis and grading of cervical intraepithelial neoplasia.** *BMJ* 1989, **298**:707-710.
32. Klinkhamer PJ, Vooijs GP, De Haan AF: **Intraobserver and interobserver variability in the diagnosis of epithelial abnormalities in cervical smears.** *Acta Cytol* 1988, **32**:794-799.
33. Alvarez-Santin C, Sica A, Rodriguez MC, Feijo A, Garrido G: **Microglandular hyperplasia of the uterine cervix: Cytologic diagnosis in cervical smears.** *Acta Cytol* 1999, **43**:110-113.
34. Ayer B, Pacey F, Greenberg M: **The cytological diagnoses of adenocarcinoma in situ of the cervix uterine and related lesions: III. Pitfalls in diagnoses.** *Acta Cytol* 1988, **32**:325-330.
35. Benoit JL, Kini SR: **Arias-Stella reaction-like changes in endocervical glandular epithelium in cervical smears during pregnancy and post partum states: A potential diagnostic pitfall.** *Diagn Cytopathol* 1996, **14**:349-355.
36. Cenci M, Mancini R, Nofroni I, Vecchione A: **Endocervical atypical glandular cells of undetermined significance. I. Morphometric and cytological characterization of cases that "cannot rule out adenocarcinoma in situ".** *Acta Cytol* 2000, **44**:319-325.
37. Selvaggi SM, Haefner HK: **Microglandular endocervical hyperplasia and tubal metaplasia: Pitfalls in the diagnosis of adenocarcinoma on cervical smears.** *Diagn Cytopathol* 1997, **16**:168-173.
38. Yates WA, Persad RV, Stambridge CM: **The Arias-Stella reaction in the cervix: A case report with cervical cytology.** *Cytopathology* 1997, **8**:40-44.
39. Veljovich DS, Stoler MH, Andersen WA, Covell JL, Rice LW: **Atypical glandular cells of undetermined significance.** *Am J Obstet Gynecol* 1998, **179**:382-390.
40. Cox JT: **ASCCP Practice Guidelines: management of glandular abnormalities in the cervico-vaginal smears.** *J Lower Gen Tract Dis* 1997, **1**:41-45.
41. Wright TC Jr, Cox JT, Massad LS, Twigg LB, Wilkinson EJ: **2001 consensus guidelines for the management of women with cervical cytological abnormalities.** *JAMA* 2002, **287**:2120-2129.

Pre-publication history

The pre-publication history for this paper can be accessed here:

<http://www.biomedcentral.com/1471-2407/4/37/prepub>

Publish with **BioMed Central** and every scientist can read your work free of charge

"BioMed Central will be the most significant development for disseminating the results of biomedical research in our lifetime."

Sir Paul Nurse, Cancer Research UK

Your research papers will be:

- available free of charge to the entire biomedical community
- peer reviewed and published immediately upon acceptance
- cited in PubMed and archived on PubMed Central
- yours — you keep the copyright

Submit your manuscript here:
http://www.biomedcentral.com/info/publishing_adv.asp

